


PRESENTING CLINICAL SIGNS

History: Chronic cough. Initially responded to antibiotics, but cough returned and has persisted despite antibiotic, antihistamine, and steroid therapy. Typically worse at night or when excited. X-rays WNL.

DATE

3/31/23

ECHOCARDIOGRAPHIC FINDINGS

2D, M-mode, and Doppler study.

PERFORMED BY:

Kim Liedberg

Left atrial size is normal. The mitral valve is normal. Left ventricular dimensions are normal. Left ventricular systolic function is normal. The aorta and aortic valve are normal. Right atrial and right ventricular dimensions are normal. The tricuspid valve is normal. The pulmonary artery and pulmonic valve appear normal, though trace pulmonic insufficiency is present. No shunting lesions are visualized. No heartworms are visualized. No pericardial effusion or cardiac masses are seen.

INTERPRETED BY

 Keith Blass, DVM,
 MS, DACVIM
 (Cardiology)

LA - 26.0 mm
 LVIDd - 26.3 mm
 LVIDs - 15.2 mm
 FS - 42%
 RA - 18.9 mm
 LVOT - 1.34 m/s
 RVOT - 0.65 m/s

PATIENT

Walt Izen

SPECIES

Canine

ASSESSMENT/RECOMMENDATIONS

Normal echocardiogram

This examination demonstrates no evidence of structural heart disease. As such, no reason for Walt's cough is appreciated in the image set.

BREED

Poodle Mix

Given the persistence of Walt's cough despite multiple therapies, more advanced diagnostics, such as tracheal fluoroscopy and/or tracheoscopy, as well as bronchoscopy/bronchoalveolar lavage, can be considered to further evaluate the cough.

No therapy is recommended based on Walt's echocardiogram.

SEX

A recheck echocardiogram is recommended if new physical exam and/or clinical abnormalities suggestive of the presence of cardiac dysfunction develop.

MN
AGE

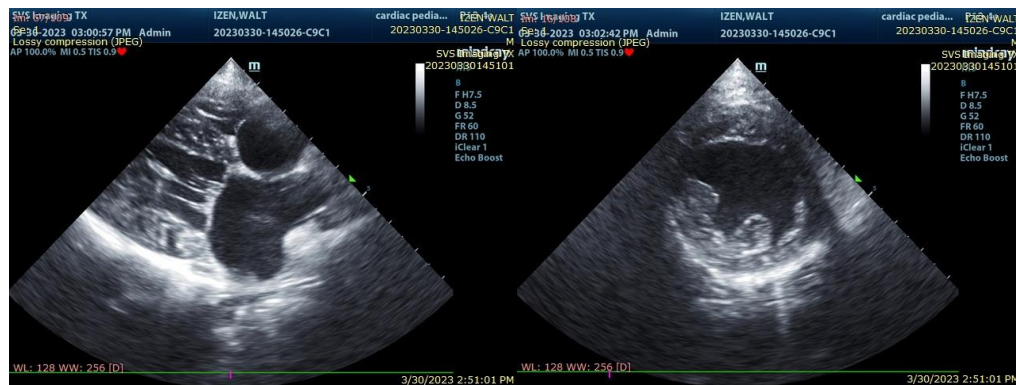
3 y

WEIGHT

20.6 lb

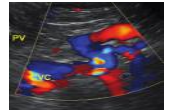
HOSPITAL NAME

SVS Imaging WI


REFERRING VET

Dr. Preiser

The information and recommendations provided are based on the images presented by the referring veterinarian. No evaluation can be communicated regarding pathology that was not



visible in the image/video clips provided.

DATE

Thank you for this referral. If the clinical or image interpretation does not parallel your findings or if I can be of any further assistance please contact me.

3/31/23

PERFORMED BY:

Keith Blass, DVM, MS, DACVIM (Cardiology)
KeithBlass@gmail.com
631-804-5754

Kim Liedberg

INTERPRETED BY

Keith Blass, DVM,
MS, DACVIM
(Cardiology)

PATIENT

Walt Izen

SPECIES

Canine

BREED

Poodle Mix

SEX

MN

AGE

3 y

WEIGHT

20.6 lb

HOSPITAL NAME

SVS Imaging WI

REFERRING VET

Dr. Preiser